



PATIENT

Reaver Vazquez
Martinez

SPECIES

Canine

BREED

Mixed

SEX

MN

AGE

1.9yr

WEIGHT

60lb

INTERPRETED BY

R. McKenzie Daniel,
DVM, DABVP
(Canine and Feline)

IMAGING PERFORMED BY

Cutrone

HOSPITAL NAME

Greater Staten Island
Veterinary Srerrvice

REFERRING VET

Brackett

INVOICE

22875

DATE

11/07/2025

PRESENTING CLINICAL SIGNS

Historical intermittent diarrhea. Presented for hematochezia

Abnormal PE/Chem/CBC/UA Results: CBC: lack of stress leukogram, otherwise WNL Chemistry: WNL Baseline Cortisol: 0.66 ug/dL (L) post ACTH stim Cortisol: 8.99 ug/dL (H/N)

ULTRASONOGRAPHIC EXAMINATION OF THE ABDOMEN

Urinary System

The urinary bladder, trigone, cystourethral junction, and visible pelvic urethra exhibited normal thickness and tone. Anechoic urine was present in the lumen with no evidence of urine/lumen sediment, mineral, or calculi. The ureteral papillae were normal. The ureters were not visible which is normal. No evidence of inflammatory or neoplastic changes was noted.

Normal size and margination were present in the kidneys. A normal 1:3 cortex / medulla ratio and normal corticomedullary definition were maintained. The echogenicity of the cortex was similar to or slightly less than normal liver parenchyma while the medulla echogenicity was hypoechoic to the cortex with no evidence of pelvic dilation. The left kidney measured 6.5 cm in length. The right kidney measured 6.5 cm in length.

The area of the aortic trifurcation was free of pathology.

The residual prostate appeared normal and free of pathology

Adrenal Glands

The left adrenal gland was uniform in size and contour with a uniformly hypoechoic parenchyma. The left adrenal gland measured 0.62 cm width at the caudal pole. The right adrenal gland was uniform in size and contour with a uniformly hypoechoic parenchyma. The right adrenal gland measured 0.71 cm width at the caudal pole.

Spleen

The spleen exhibited a finely textured and homogenous parenchyma which was hyperechoic to the liver and renal cortical parenchyma. The capsule was smooth and regular without apparent expansion. The splenic vasculature at the hilus was normal in volume with no evidence of congestion or thrombosis. Acute to chronic inflammatory, neoplastic, or benign parenchyma changes were not noted.

Liver/Gallbladder

The liver was subjectively normal in size, structure, and contour. The liver parenchyma was uniform and hypoechoic to the spleen with a mild coarse echotexture. Normal vascular volume. The hepatic and portal vasculature were normal in appearance without signs of congestion. The gallbladder was non-distended in size with thin walls and primarily anechoic luminal content. The cystic and common bile ducts were normal.

Gastrointestinal

The stomach presented intact wall layering with a normal wall layer ratio. The lumen of the stomach was empty with no signs of ileus, obstruction or foreign material.



PATIENT

Reaver Vazquez
Martinez

The small intestine presented intact wall layering with 1:3 muscularis/mucosa ratio. The lumen of the small intestine was empty with no signs of mechanical/metabolic ileus, obstruction or foreign material.

Normal visible colon wall layers were present with semi formed feces in lumen.

SPECIES

Canine

Pancreas

The parenchyma of the left limb, body and right limb of the pancreas presented isoechoic to the adjacent omental fat. A normal curvilinear capsule contour of the pancreas was present. The visible pancreatic duct was normal. No signs of active inflammation or neoplastic disease was evident.

BREED

Mixed

Free Abdomen

No omental masses, overt lymphadenopathy or peritoneal effusion was present.

SEX

MN

ULTRASONOGRAPHIC FINDINGS

Primary

- Sonographically unremarkable abdomen
- Semi-formed fecal matter in colon

AGE

1.9yr

INTERPRETATION OF THE FINDINGS & FURTHER RECOMMENDATIONS

No evidence of visceral, specifically gastroenterocolic pathology. Mild colitis is probable in conjunction with hematochezia. Dietary intolerance, infectious disease, non-structural inflammatory bowel, occult parasitism, all possible. A fresh fecal analysis is recommended to rule out parasitic ova/giardia. A GI panel to include PLI/TLI/Cobalamin/Folate is recommended.

WEIGHT

60lb

INTERPRETED BY

R. McKenzie Daniel,
DVM, DABVP
(Canine and Feline)

Empirically, a limited antigen or hydrolyzed diet trial with potential long term dietary therapy, prophylactic deworming (Panacur 50 mg/kg SID x 5 consecutive days with repeat protocol in 3 weeks even if fecal testing is negative), high colony count probiotic (Provable or Visbiome) and as needed gastroprotectants may prove beneficial.

IMAGING PERFORMED BY

Cutrone

HOSPITAL NAME

Greater Staten Island
Veterinary Serrvice

REFERRING VET

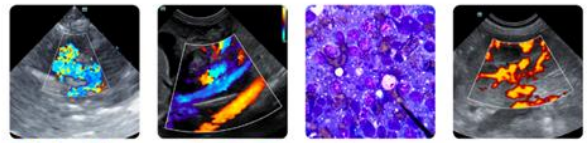
Brackett

INVOICE

22875

DATE

11/07/2025



PATIENT

Reaver Vazquez
Martinez

SPECIES

Canine

BREED

Mixed

SEX

MN

AGE

1.9yr

WEIGHT

60lb

INTERPRETED BY

R. McKenzie Daniel,
DVM, DABVP
(Canine and Feline)

**IMAGING
PERFORMED BY**

Cutrone

HOSPITAL NAME

Greater Staten Island
Veterinary Serrvice

REFERRING VET

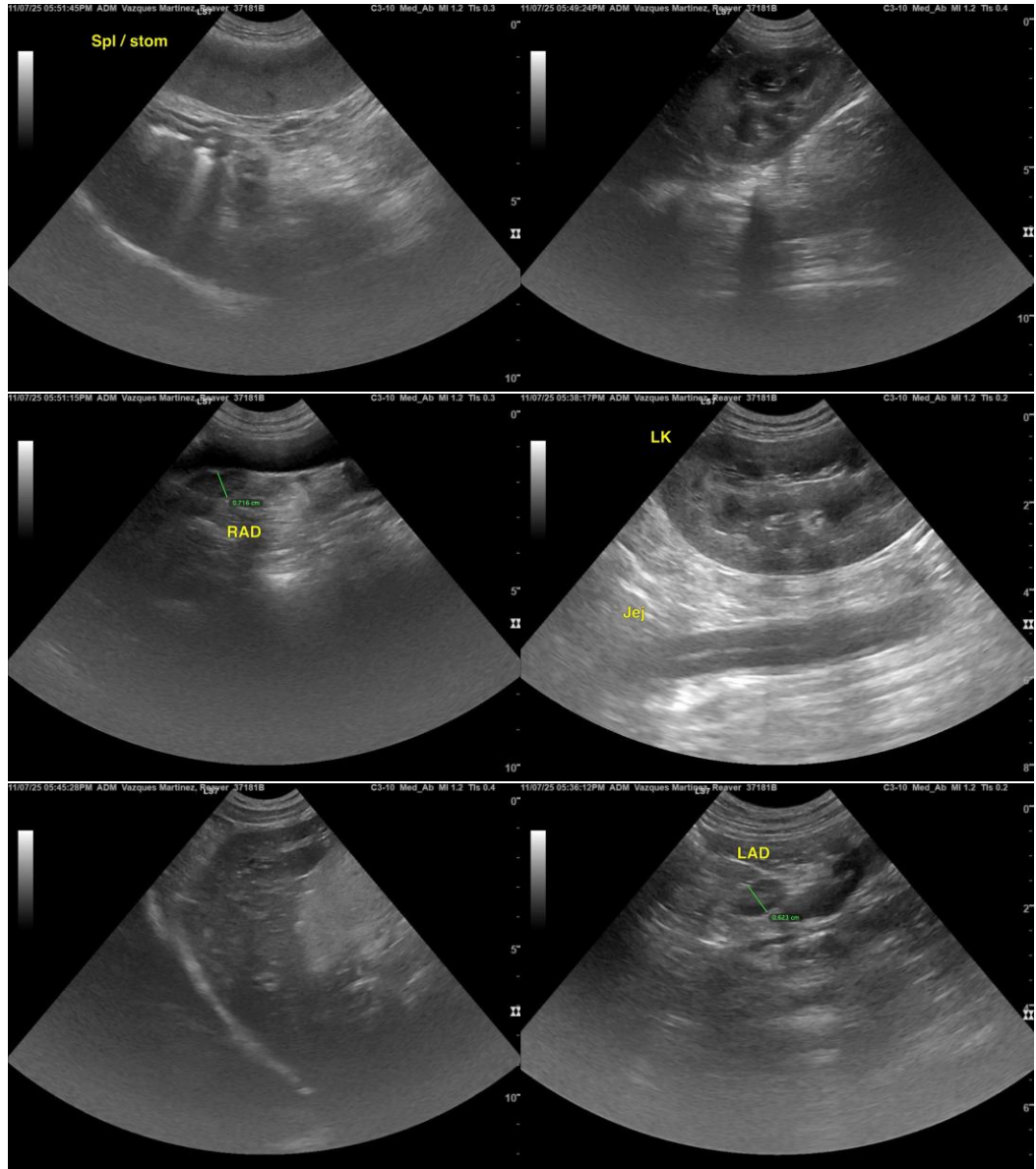
Brackett

INVOICE

22875

DATE

11/07/2025





PATIENT

Reaver Vazquez
Martinez

SPECIES

Canine

BREED

Mixed

SEX

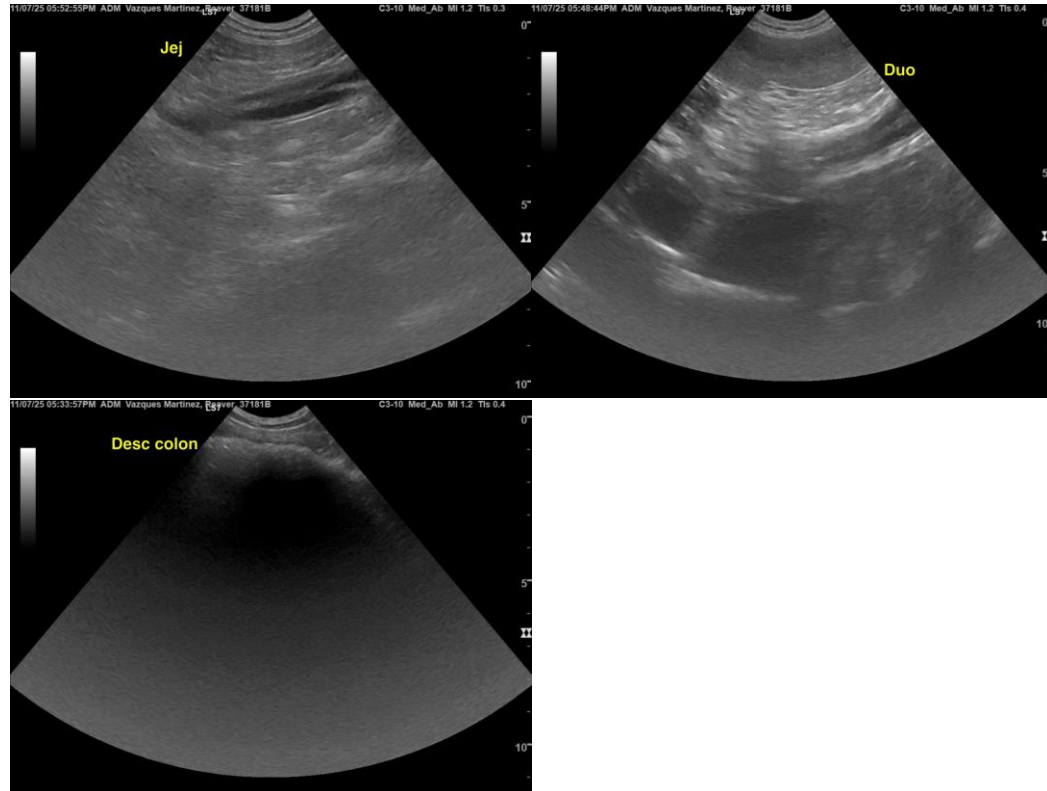
MN

AGE

1.9yr

WEIGHT

60lb



INTERPRETED BY

R. McKenzie Daniel,
DVM, DABVP
(Canine and Feline)

IMAGING PERFORMED BY

Cutrone

HOSPITAL NAME

Greater Staten Island
Veterinary Service

REFERRING VET

Brackett

INVOICE

22875

DATE

11/07/2025

The information and recommendations provided are based on the images presented by the referring veterinarian/sonographer. No evaluation can be communicated regarding pathology that was not visible in the image/video clips provided.

Thank you for this referral. If the clinical or image interpretation does not parallel your findings or if I can be of any further assistance, please contact me.

R. McKenzie Daniel, DVM, DABVP (Canine/Feline Practice)
info@sonopath.com